

Pro and Anti-Inflammatory Factors in Patients with Rhegmatogenous Retinal Detachment with Silicone Oil Tamponade



Ahdini Zulfiana Abidin¹, Budu^{1,2*}, Andi Muhammad Ichsan^{1,2},
Habibah Setyawati Muhiddin^{1,2}, Hasnah Eka^{1,2}

ABSTRACT

Introduction: Rhegmatogenous retinal detachment (RRD) is the most common type of detachment, followed by exudative and tractional detachment. Pathogenic changes in the retina (including angiogenesis and fibrosis) trigger local inflammation and infiltration of leukocytes of the choroid, retina, and vitreous, which is also found in proliferative vitreoretinal detachment. Silicone oil, as a temporary tamponade used in the RRD, can cause immunological reactions in the tissue and may become one of the causes of increasing levels of inflammatory mediators in the eye. This literature review aims to determine the pro- and anti-inflammatory factors found in patients with RRD and patients with silicone oil tamponade.

Methods: This literature review utilised reliable databases such as Pubmed, Proquest, and Google Scholar from 2013 until 2023. The main keywords "rhegmatogenous retinal detachment" and "silicone oil" were used, including some additional keywords, to collect eight journals that had relevant topics.

Result: Variations of inflammatory markers were found in many studies, and some correlated with proliferative vitreoretinopathy (PVR) development, the extent of detachment and the recurrence of redetachment in some cases.

Conclusion: A rise in various cytokines can mediate the wound-healing process in RRD, specifically involving retinal pigment epithelium and glial cells, fibroblasts, and inflammatory cells in eyes with retinal tears. This trend of high activity of RPE cells also appeared in eyes with vitreous cavities replaced by silicone oil (SO). The selection of tamponade preference should be based on the extent of the injury, patients' needs, and surgeons' expertise.

Keywords: rhegmatogenous retinal detachment; silicone oil; inflammatory markers, intra-ocular tamponade.

Cite This Article: Abidin, A.Z., Budu., Ichsan, A.M., Muhiddin, H.S., Eka, H. 2024. Pro and Anti-Inflammatory Factors in Patients with Rhegmatogenous Retinal Detachment with Silicone Oil Tamponade. *Bali Medical Journal* 13(1): 350-355. DOI: 10.15562/bmj.v13i1.5067

¹Department of Ophthalmology, Faculty of Medicine, Universitas Hasanuddin Makassar, Indonesia

²Universitas Hasanuddin Hospital, Makassar, Indonesia

*Corresponding to:

Nurussyariah Hammad; Department of Neurology, Faculty of Medicine, Universitas Hasanuddin, Indonesia; Department of Nutrition, Faculty of Sport and Health Sciences, Universitas Negeri Makassar, Indonesia;
nurussyariah@unm.ac.id.

Received: 2023-10-04

Accepted: 2023-12-01

Published: 2023-12-30

INTRODUCTION

Rhegmatogenous retinal detachment is the most prevalent type, followed by exudative and tractional detachment. Rhegmatogenous retinal detachment separates the retina's neurosensory layer from the retinal pigment epithelium layer caused by fluid penetration into the subretinal space via one or more retinal tears.^{1,2}

Pathogenic changes in the retina (such as angiogenesis and fibrosis) cause local inflammation and infiltration of choroid, retina, and vitreous leukocytes, also seen in proliferative vitreoretinal detachment. Although leukocyte infiltration can occur for various reasons, it can also harm the retinal layer.²

Rhegmatogenous retinal detachment often requires vitrectomy due to its

persistent impact; silicone oil is frequently employed as an intraocular tamponade. However, its application may result in complications due to disruptions in the intraocular energy metabolism and damage to normally functioning ocular tissue. Several complications, including epiretinal membrane formation, cataracts, glaucoma, and keratopathy, are possible outcomes. However, cerebral migration and visual impairment are comparatively infrequent complications associated with silicone oil (SO) tamponade.³

Injecting temporary vitreous substitution in gas or SO into the vitreous cavity works as a retinal tamponade measure until laser or cryo-cancerization can be utilized to seal the retinal fissure. Silicone oil finds utility primarily in the treatment of chronic retinal tamponade and is frequently used

in surgical procedures involving retinal detachment, including proliferative vitreoretinopathy, retinal traction, and retinal tears. The viscosity of silicone oil varies, but it typically ranges between 1000 and 6000 mPa s, with a choice of 5000 mPa s.⁴⁻⁶

Correlations exist between interleukin-6 (IL-6), IL-8, and monocyte chemoattract protein-1 (MCP-1), all pro-inflammatory factors frequently observed in RRD. These three factors suggest that vitreoretinal disease is associated with particular mechanisms. IL-6 is a multifunctional cytokine that induces the expression of vascular endothelial growth factor (VEGF), thereby indirectly increasing vascular permeability. A biological vitreous sample from patients with RRD revealed elevated levels of IL-6 compared to non-RRD patients.

This discovery indicated that IL-6 is involved in preserving photoreceptors following detachment. IL-8 is produced by endothelial and glial cells in the retina during ischemic angiogenesis. Dendritic cells, memory T cells, and monocytes are drawn to sites of tissue damage and infection by MCP-1; therefore, its upregulation may facilitate the infiltration of inflammatory cells into the eye. IL-4 in patients with RRD were also found higher in AH and vitreous when compared with patients with macular holes, which also showed a similarity of level in both specimens.^{2,7,8}

Silicone oil has variable biocompatibility as tamponade and can cause ocular tissue and immunological reactions after injection. Silicone oil can induce the growth of macrophages and immunoproteins in the eye, entering the anterior segment and the retina. Another investigation discovered that silicone oil tamponade elevated the concentrations of mediators of inflammation, such as IL-6 and TNF-alpha, in glaucoma patients' aqueous humour.^{9,10} This literature review aims to know the pro and anti-inflammatory factors found in patients with RRD and patients with silicone oil tamponade.

METHODS

Literature Review

This literature review is cited from reliable sources such as PubMed, ProQuest and Google Scholar. It utilised a database from 2013 until 2023. The keywords "rhegmatogenous retinal detachment" and "silicone oil" were used, including additional keywords described in [Table 1](#). The articles included are full-text and in English. The bias risk assessment was conducted utilising the ROBIN I tools

Study selections

The reports were considered eligible if they met the following inclusion criteria: (1) subjects are patients with rhegmatogenous retinal detachment; (2) undergo vitrectomy; and (3) inflammatory markers levels examined. The search was limited to articles with a human sample, subject areas of medicine published in English, and available full-text reviews and articles. Exclusion criteria: (1) secondary article

Table 1. Keywords in each database

Database	Keywords	Results
PubMed	"rhegmatogenous retinal detachment" and "silicone oil"	19 articles
	"rhegmatogenous retinal detachment" "inflammation"	12 articles
	"silicone oil", "inflammation"	12 articles
Google Scholar	"rhegmatogenous retinal detachment", "silicone oil", "pro-inflammatory", and "anti-inflammatory"	62 articles
	"rhegmatogenous retinal detachment", "silicone oil", and "interleukin"	188 articles
	"rhegmatogenous retinal detachment", "silicone oil", and "inflammatory markers"	31 articles
ProQuest	"rhegmatogenous retinal detachment", "silicone oil", and "inflammatory markers"	Ten articles
	"rhegmatogenous retinal detachment", "silicone oil", "inflammatory", and "anti-inflammatory" ¹	Five articles

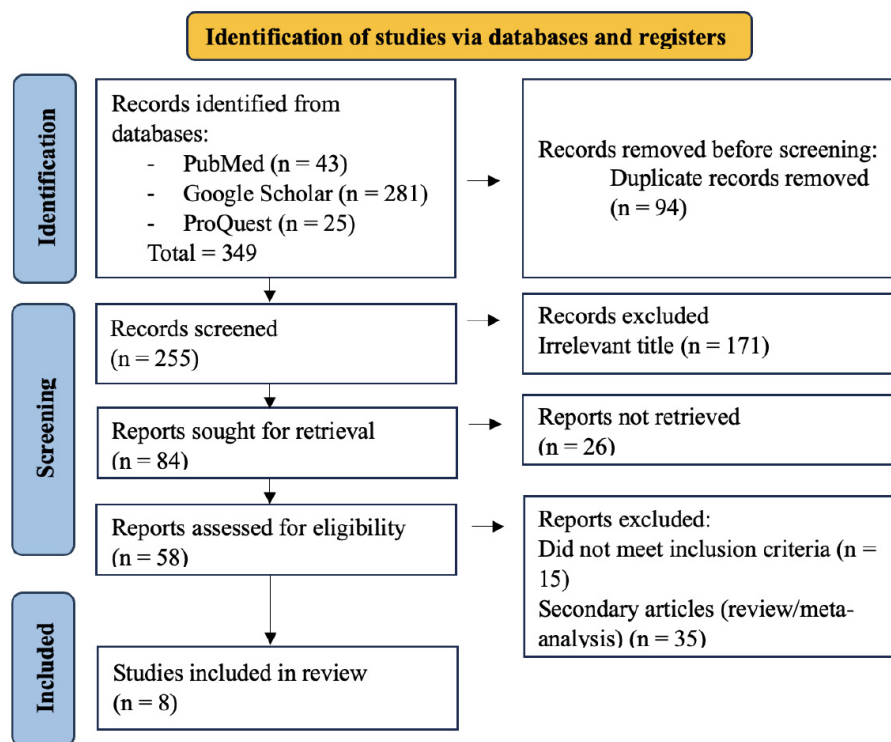


Figure 1. PRISMA flow was used in this literature review.

such as a review article, systematic review, or editorial; (2) case report, case series, or animal experiment; and (3) other type of retinal detachment.

Data Processing

The collected information is then separated based on the author's name, year of publication, level of evidence of the article, total number of samples, research methods used, tamponade duration, and type and level of inflammatory markers found in the article.

RESULTS

According to this article, none of the studies have a baseline and follow-up. Thus, the inflammatory factors cannot be evaluated for their increasing or decreasing level in patients. In a search using the keywords "rhegmatogenous retinal detachment" and "silicone oil" as well as several supporting keywords that have been described previously, we obtained 349 articles, which were then selected based on the title and abstract and

Table 2. Literature Review Result of Pro and Inflammatory Factors in RRD Patients

Results	Type of Study	RRD Inflammatory Factors	Author(s), Journal Year Level of Evidence
When RRD happens, localised and systemic oxidative damage and elevated inflammatory mediators may contribute to retinal ganglion cell (RGC) apoptosis and impact postoperative vision. Monocytes produce inflammatory mediators and pro-oxidative cytokines involved in inflammation and oxidative stress.	Cross-sectional observational study	Sample: Blood Monocyte counts and (monocyte-to-high-density lipoprotein) MHR in RRD patients were significantly lower compared to control. The parameters of ganglion cell complex (GCC) thickness were considerably strongly correlated with MHR, whereas focal loss volume (FLV) and global loss volume (GLV) were the contrary.	Song et al. ¹¹ 2022 Level 3
All cytokines and chemokine and cytokine in the vitreous fluid were significantly elevated in pRD patients with or without PVR, with the exception of TGF beta-1 and -2.	Prospective study with consecutive patients	Sample: Vitreous (pg/mL) Chemokine (C-C motif) ligand 19 (CCL19) was elevated in pRD with early PVR, with 11 additional cytokines also having higher concentration in vitreous in more advanced stages of PVR, which are CCL27, CXCL6, IL4, IL6, CXCL10, CCL8, CCL22, MIG/CXCL9, CCL15, CCL23 and CXCL12)	Zandi et al. ¹² 2019 Level 3
In contrast to the control group, the eyes exhibiting detached retinas exhibited a higher concentration of the cytokine MCP-1. In comparison to the simple retinal detachment and control groups, eyes with proliferative vitreoretinopathy had higher levels of VEGF, which could be an indication of more radical options for surgery, including SO use. In addition, MCP-1 levels may be used to evaluate the timing of SO removal, with high levels contraindicating the evacuation.	Prospective Cohort Study	Sample: Aqueous Humour (pg/ml) Significant differences of EGF, FGF-2, IL-6, IL-8, IP-10, MCP-1, CNTF, and TGF- β 1 of patients with RD compared to control. Meanwhile, VEGF levels increased in RD with PVR symptoms. In patients with RD, MCP-1 levels were found to be elevated and correlated with other cytokine levels, including FGF-2, IL-6, IL-8, and IP-10.	Rusnak et al. ¹³ 2013 Level 3
In the vitreous samples, 40 different cytokines and chemokines are involved in various pathways that include inflammatory processes, angiogenesis, or growth of cells. The RRD extent and status of the lens influenced intravitreal inflammatory factors and profibrotic and proapoptotic protein expression.	Prospective Study	Sample: Vitreous (pg/mL) The levels of IL-6, -8, MCP-1, IP-10, TIMP-1, -2, TGF β -3, BDNF, PDGF-AB/BB, and MIP-1 in the vitreous of RRD eyes were significantly higher when compared with controls. Elevated concentrations of IL-8 and TGF β -3 corresponded to the quantity of detached retinal quadrants..	Pollreizs et al. ¹⁴ 2015 Level 3
Upregulated expression of inflammatory factors in vitreous patients with RRDCD and RRD had a role and may become one of the therapy options by altering the local inflammation.	Case-control Study	Sample: Vitreous (pg/mL) RRDCD had higher levels of intravitreal inflammatory mediators such as migration inhibitor factor (MIF), interleukin-6 (IL-6), CCL4, CCL11, CCL17, CCL19, CCL22, CXCL9, CXCL8, soluble inter-cellular adhesion molecule 1 (sICAM-1), transforming growth factor 3 (TGF-3), and platelet-derived growth factor AA (PDGF-AA).	Dai et al. ¹⁵ 2015 Level 4
RD induced inflammatory response along with the cytokine network. Several proteins had been found to be correlated to certain clinical signs leading to photoreceptor degeneration and redetachment or PVR.	Prospective Study	Sample: Vitreous (pg/mL) In the vitreous of RD patients, eleven mediators, including the cytokines IL-1ra, IL-6, IL-7, IL-8, and IFN-, the chemokines CCL2, CCL3, CCL4, CXCL10, and CCL11, and the growth factor G-CSF, were substantially elevated in comparison to the control group. The correlation analyses indicated that the levels of IL-1ra, CXCL10, CCL11, and G-CSF were associated with the degree of detachment, whereas IL-1ra and CXCL10 were correlated with the duration of detachment.	Conart et al., ¹⁶ 2021 Level 3

Table 3. Literature Review Result of SO-filled Eyes Inflammatory Factors

Results	Type of Study	SO-filled Eyes Inflammatory Factors	Author(s), Journal Year Level of Evidence
A total of twenty-seven cytokine profiles exhibited variations in eyes with high intraocular pressure (IOP). Notably, postoperative patients with high IOP had substantially elevated levels of VEGF, IL-6, FGF2, and G-CSF, whereas VEGFR decreased.	Prospective study	Sample: Aqueous Humour (pg/mL) In RD patients with high IOP, VEGF, IL-6, FGF1, and G-CSF levels were significantly elevated following PPV, whereas VEGFR2 levels were substantially decreased, IL-6 had an essential correlation with high IOP. IL-6, an essential variable in developing fibrosis and inflammation, works with VEGF, FGF2, and G-CSF to regulate inflammatory processes and repair postoperative PPV eyes.	Zhu et al. ¹⁷ 2023 Level 3
The ratio of neutrophils to lymphocytes and the index of system immune inflammation may become the biomarkers for RRD patients, especially in predicting the risk of PVR.	Retrospective Comparative Study	Sample: Blood Mean white blood cell, neutrophil, and monocyte levels increased significantly in RRD with PVR compared to RRD only those who underwent PPV and/or PPV and phacoemulsification with IOL implantation.	Koçak et al. ¹⁸ 2023 Level 3

filtered again according to the inclusion and exclusion criteria, resulting in a total of 8 studies (six studies for literature review result of pro and inflammatory factors in RRD patients (Table 2) and two studies literature review result of SO-filled eyes inflammatory factors (Table 3) included in this literature review (Figure 1).

Several chemokine and inflammatory factors have been examined that link into RRD, including CCL19, CCL27, CXCL6, IL4, IL6, CXCL10, CCL8, CCL22, MIG/CXCL9, CCL15, CCL23 and CXCL12), EGF, FGF-2, IL-6, IL-8, IP-10, MCP-1, CNTF, TGF-β1, TGF-β3, IL-8, IP-10 and IL-6. Those inflammatory factors increase in RRD groups and are higher than in the control group. Its inflammatory factor could be detected in blood, vitreous, and aqueous humour (Table 2).

The bias risk assessment was conducted utilizing the ROBINS I tool. Most of the study had low risk of bias. Pollreisz et al had moderate bias analysis. Due to non-specific inclusion and exclusion criteria, there were statements of missing data in this study, and it also impacted the results. However, the other components have been explained well in this study. Most of the studies had a bias due to intervention classification and deviation due to the intended intervention (Figure 2).

DISCUSSION

This literature review found seven articles on pro and anti-inflammatory factors

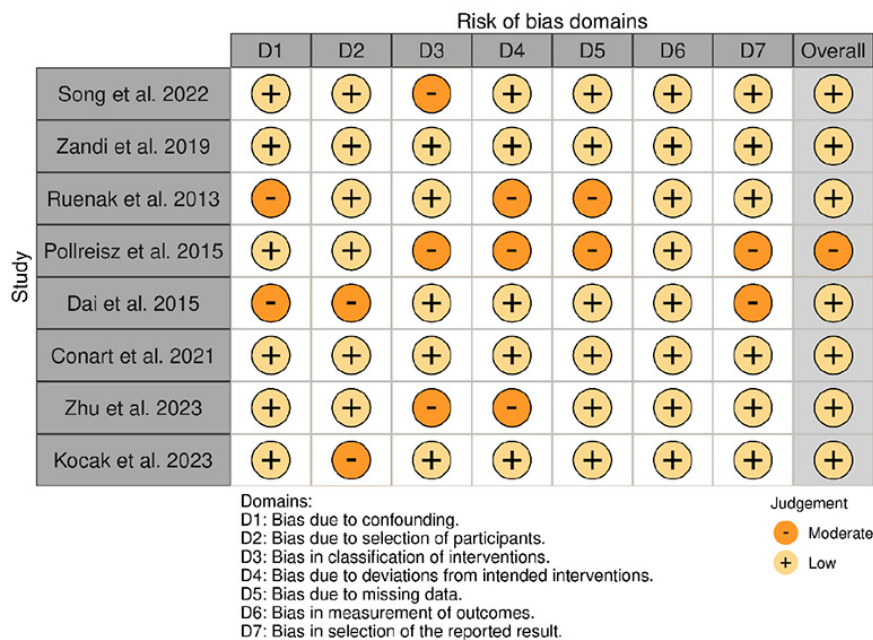


Figure 2. Risk Of Bias Analysis

in RRD patients. However, these studies have several limitations, including the follow-up results of patients with RRD with SO tamponade and baseline data of RRD patients who were followed for inflammatory factors after the duration of SO tamponade.

Studies on SO tamponade and its inflammation in RRD patients are limited but show increasing inflammatory markers in various samples, including blood, AH, and vitreous. Some inflammatory factors show significant increases related to the extent, duration, complication, and

presence of PVR in RRD.

Many studies found varied inflammatory markers and inflammation response correlated with proliferative vitreoretinopathy (PVR) development and the recurrence of redetachment in some cases. An additional experimental investigation found detached retinas have greater MCP-1 and TNF-α. This suggests that inflammatory responses may alter the aetiology of photoreceptor loss and PVR in RRD.¹⁹⁻²¹

Inflammatory factors such as chemokines and cytokines were

significantly more prevalent in RRD patients' vitreous samples when compared to controls with idiopathic epiretinal membranes before vitrectomy, which revealed in the statistical calculation using a linear regression method that IL-8 and TGF-3 raised with the extent of detached retinal quadrants. At the same time, TIMP-1 increased in eyes with greater RD heights. The severity of RRD influences intravitreal pro-inflammatory, proinflammatory, and proapoptotic protein expression. The levels of PDGF-AA, sICAM-1, TGF-3, MIF, IL-6, CCL4, CCL11, CCL17, CCL19, CCL22, CXCL9, CXCL8, sICAM-1, and TGF-3 were all significantly lower in RRD patients than in RRDCD patients. This result is likely attributable to the increased production of inflammatory markers in vitreous or subretinal fluid from patients with RRDCD, as protein leakage is the primary source of subretinal fluid in RRDCD patients and subretinal fluid is predominantly generated from vitreous in RRD cases.^{14,15}

Vitreous samples obtained from patients with renal dysfunction (RD) exhibited elevated levels of inflammatory factors, such as growth factor G-CSF, cytokines IL-1ra, IL-6, IL-7, IL-8, and IFN- γ , and chemokines CCL2, CCL3, CCL4, CXCL10, and CCL11. Notably, the majority of the elevated cytokines exhibited interrelationships, suggesting the existence of a vast network of cytokines in RD vitreous. IL-6 is hypothesized to be a key factor in inflammation and fibrosis; it regulates eye inflammation post-PPV, and it forms an inflammatory network with VEGF, FGF2, and G-CSF, according to another study that used AH as a model.^{16,17}

Shimizu et al. discovered that the expression of IL-8 and MCP-1 was higher in eyes with silicone oil tamponade in his study that observed the concentrations of inflammatory cytokines and electrolytes in eyes with SO tamponade and compared them with the vitreous fluid and anterior chamber.²² A significant positive relationship was also found between the IL-6 and IL-8 levels and the duration of tamponade use in retinal detachment with silicone oil tamponade. Another study also suggested that RPE cells had high activity in eyes with SO compared to gas-filled or fluid-filled eyes.^{22,23}

The limitations of the study are

because there is no similar study had been conducted before, and all the studies included in this literature review only inflammatory factors in RRD patients before they underwent the PPV and after the PPV without any baseline and follow-up.

CONCLUSION

A rise in a variety of cytokines that can mediate the process of wound healing involves retinal pigment epithelium and glial cells, fibroblasts, and inflammatory cells in eyes with retinal tears. Cytokine levels in eyes with pseudophakic and phakic retinal detachment showed similar trends in the vitreous and the aqueous humour, as did the severity and duration of retinal detachment. Inflammatory markers are found to be elevated in RRD patients, especially if complicated by PVR, longer time, and extent of detachment. This trend also appeared in eyes with vitreous cavities replaced by SO.

The decision of tamponade choice should be made based on the severity, patients' needs, and surgeons' expertise. Removal of the tamponade is needed if the surgeons choose to use silicone oil, and this should consider the anatomical goal of the attached retina and recovery process, which are different for every individual.

AUTHOR CONTRIBUTION

Writing – original draft, Writing – review & editing, Funding acquisition, Investigation, Methodology, Resources, Validation, Visualisation, Conceptualization, Data curation, Formal analysis, Project administration, Ahdini Zulfiana Abidin. In addition to conceptualization, data curation, formal analysis, funding acquisition, investigation, supervision, methodology, resources, validation, and visualisation, Budu is responsible for writing the original draft and revising and refining the writing. Andi Muhammad Ichsan: Investigation, Methodology, Supervision, Resources, Software, Validation, Visualisation, Writing – review & editing; Conceptualization; Data curation; Formal analysis; Writing – review & editing. Conceptualization, Data curation, Formal analysis, Investigation, Methodology, Supervision, Resources, Software, Validation, Visualisation,

Writing – review and editing are all areas of expertise for Habibah Setyawati Muhiddin. Review and revision of writing, Hasnah Eka: conceptualization, data curation, formal analysis, investigation, methodology, supervision, resources, software, validation, and visualisation.

FUNDING

The authors have no external support or funding.

CONFLICT OF INTEREST

None of the authors present a conflict of interest.

REFERENCES

1. Cantor LB, Rapuano CJ, Cioffi GA. Basic and Clinical Science Course: Glaucoma. 10th ed. San Francisco: American Academy of Ophthalmology; 2018. 1–16 p.
2. Yoshimura T, Sonoda K-H, Sugahara M, Mochizuki Y, Enaida H, Oshima Y, et al. Comprehensive Analysis of Inflammatory Immune Mediators in Vitreoretinal Diseases. *PLoS One*. 2009;4(12):e8158.
3. Ohji M. Unexpected complications related to tamponade after vitrectomy. Vol. 254, Graefe's Archive for Clinical and Experimental Ophthalmology. Springer Verlag; 2016. p. 1463–4.
4. Colthurst MJ, Williams RL, Hiscott PS, Grierson I. Biomaterials used in the posterior segment of the eye. *Biomaterials*. 2000;21(7):649–65.
5. Su X, Tan MJ, Li Z, Wong M, Rajamani L, Lingam G, et al. Recent Progress in Using Biomaterials as Vitreous Substitutes. *Biomacromolecules*. 2015;16(10):3093–102.
6. Yadav I, Purohit SD, Singh H, Bhushan S, Yadav MK, Velpandian T, et al. Vitreous substitutes: An overview of the properties, importance, and development. *J Biomed Mater Res B Appl Biomater*. 2021;109(8):1156–76.
7. Asensio-Sánchez VM, Collazos JM, Cantón M. Concentración de interleuquina-6 en el vítreo de pacientes con desprendimiento de retina. *Arch Soc Esp Oftalmol*. 2015;90(11):527–30.
8. Garweg JG, Zandi S, Pfister I, Rieben R, Skowronska M, Tappeiner C. Cytokine profiles of phakic and pseudophakic eyes with primary retinal detachment. *Acta Ophthalmol*. 2019;97(4).
9. Versura P, Cellini M, Torreggiani A, Bernabini B, Rossi A, Moretti M, et al. The Biocompatibility of Silicone, Fluorosilicone and Perfluorocarbon Liquids as Vitreous Tamponades. *Ophthalmologica*. 2001;215(4):276–83.
10. Liu Z, Fu G, Liu A. The relationship between inflammatory mediator expression in the aqueous humor and secondary glaucoma incidence after silicone oil tamponade. *Exp Ther Med*. 2017;
11. Song J, Chen T, Zuo W, Chen W, Lei M, Ai

- M. Changes of retinal ganglion cell complex after vitrectomy in rhegmatogenous retinal detachment patients and its correlation with inflammatory blood biomarkers. *BMC Ophthalmol.* 2022;22(1):290.
12. Zandi S, Pfister IB, Trainee PG, Tappeiner C, Despont A, Rieben R, et al. Biomarkers for PVR in rhegmatogenous retinal detachment. *PLoS One.* 2019;14(4):e0214674.
 13. Rusnak S, Vrzalova J, Hecová L, Kozova M, Topolcan O, Ricarova R. Defining the seriousness of proliferative vitreoretinopathy by aspiration of cytokines from the anterior chamber. *Biomark Med.* 2013;7(5):759–67.
 14. Pollreis A, Sacu S, Eibenberger K, Funk M, Kivaranovic D, Zlabinger GJ, et al. Extent of Detached Retina and Lens Status Influence Intravitreal Protein Expression in Rhegmatogenous Retinal Detachment. *Investigative Ophthalmology & Visual Science.* 2015;56(9):5493.
 15. Dai Y, Wu Z, Sheng H, Zhang Z, Yu M, Zhang Q. Identification of inflammatory mediators in patients with rhegmatogenous retinal detachment associated with choroidal detachment. *Mol Vis.* 2015;21:417–27.
 16. Conart J-B, Augustin S, Remen T, Sahel J-A, Guillonnet X, Delarasse C, et al. Vitreous cytokine expression profiles in patients with retinal detachment. *J Fr Ophtalmol.* 2021;44(9):1349–57.
 17. Zhu C, Cheng Y, Tang Y, Wu H. Changes of aqueous humor cytokine profiles of patients with high intraocular pressure after PPV for retinal detachment. <https://www.researchsquare.com/article/rs-3288564/late.2023>.
 18. Koçak N, Erduran B, Yeter V. Predictive values of systemic inflammation biomarkers in proliferative vitreoretinopathy associated with primary rhegmatogenous retinal detachment. *Clin Exp Optom.* 2023;106(8):852–8.
 19. Nakazawa T, Kayama M, Ryu M, Kunikata H, Watanabe R, Yasuda M, et al. Tumor Necrosis Factor- α Mediates Photoreceptor Death in a Rodent Model of Retinal Detachment. *Investigative Ophthalmology & Visual Science.* 2011;52(3):1384.
 20. Nakazawa T, Matsubara A, Noda K, Hisatomi T, She H, Skondra D, et al. Characterization of cytokine responses to retinal detachment in rats. *Mol Vis.* 2006;12:867–78.
 21. Prasad M, Xu J, Agranat JS, Xia W, Daley S, Ness S, et al. Upregulation of Neuroinflammatory Protein Biomarkers in Acute Rhegmatogenous Retinal Detachments. *Life.* 2022;13(1):118.
 22. Shimizu H, Kaneko H, Suzumura A, Takayama K, Namba R, Funahashi Y, et al. Biological Characteristics of Subsilicone Oil Fluid and Differences With Other Ocular Humors. *Transl Vis Sci Technol.* 2019;8(1).
 23. Kaneko H, Takayama K, Asami T, Ito Y, Tsunekawa T, Iwase T, et al. Cytokine profiling in the sub-silicone oil fluid after vitrectomy surgeries for refractory retinal diseases. *Sci Rep.* 2017;7(1):2640.



This work is licensed under a Creative Commons Attribution